



Cover image

Type 3 SLAP: bucket handle tear

SLAP de tipo 3: desgarró en asa de cubo

K. Rodríguez Bascones

Shoulder and Elbow Unit. ASEPEYO Sant Cugat. Barcelona (Spain)

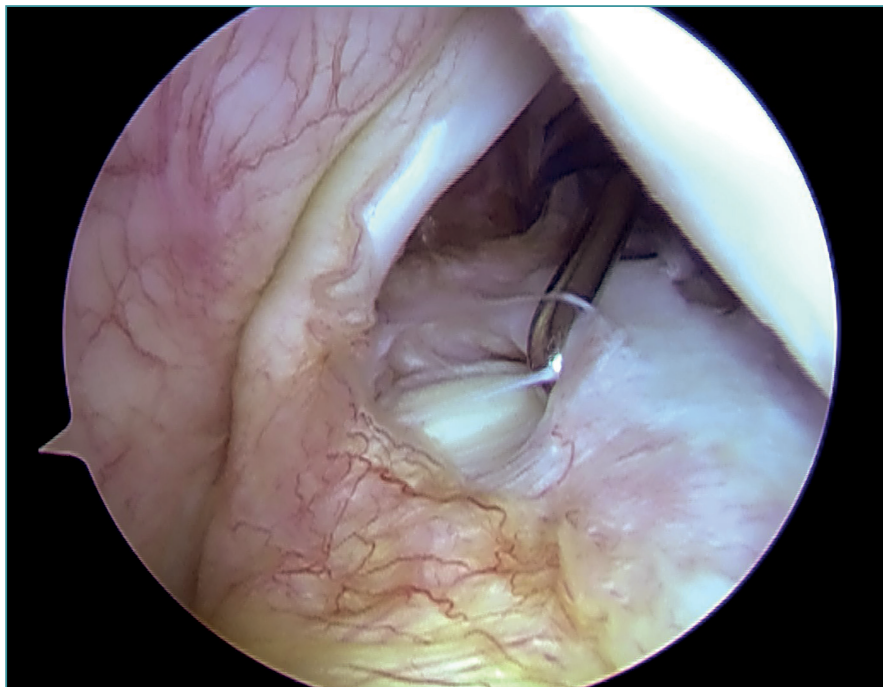
Correspondence:

Dr. Karla Rodríguez Bascones
E-mail: doctorabascones@gmail.com

Received 02 July 2021
Accepted 30 April 2022
Available online: April 2022

Arthroscopic view of the glenohumeral cavity of a right shoulder from the posterior portal, in a female patient operated upon due to relapsing shoulder dislocation. The photo shows a type 3 SLAP lesion of the bicipitalabral

complex according to the classification of Snyder. This type of lesion is characterised by a bucket handle tear of the upper *labrum*, keeping the tendon of the long portion of the biceps intact.



<https://doi.org/10.24129/j.reacae.29276.fs2107023>

© 2022 Fundación Española de Artroscopia. Published by Imaidea Interactiva in FONDOSCIENCE® (www.fondoscience.com). This is an Open Access article under licence CC BY-NC-ND (www.creativecommons.org/licenses/by-nc-nd/4.0/).