

Cover image

Inverted cyclops *Cíclope invertido*

M.J. Espejo Reina¹, A. Espejo Reina^{2,3}, A. Espejo Baena^{2,3}

¹ Hospital San Juan de Dios del Aljarafe. Bormujos, Sevilla

² Hospital Vithas Málaga

³ Clínica Espejo

Correspondence:

Dr. María Josefa Espejo Reina

E-mail: pepaespejoreina@gmail.com

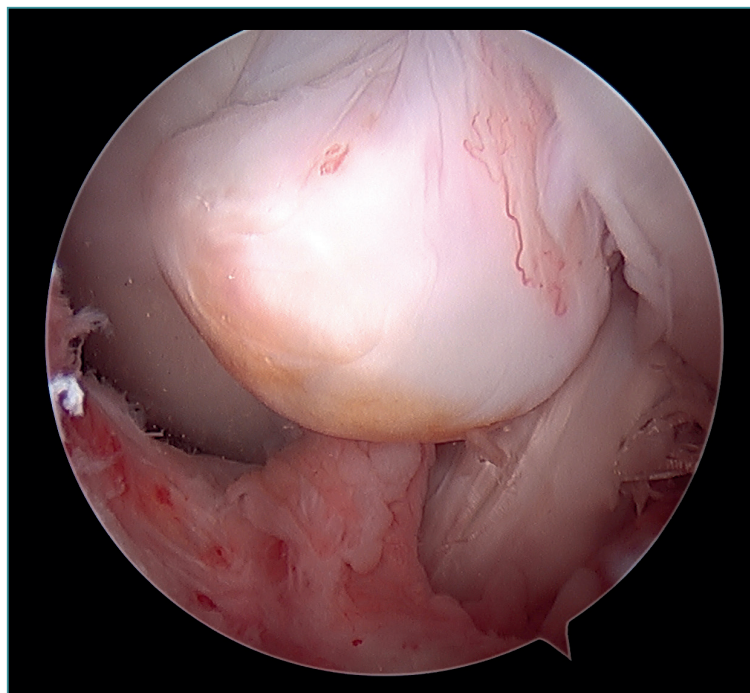
Received 18 December 2021

Accepted 19 January 2022

Available online: January 2022

Knee arthroscopy in which an inverted cyclops lesion is observed. Cyclops lesion consists of a fibrous nodule that forms at the central pivot of the knee following surgeries with an intraarticular approach. The incidence ranges between 1-10% of all knees subjected to anterior cruciate lig-

ament (ACL) ligamentoplasty, though the condition is not always symptomatic. Its most common location is at the tibial origin of the ACL. Only 5 cases involving a femoral origin, as in our case, have been reported in the literature to date.



<https://doi.org/10.24129/j.reacae.29175.fs2112042>

© 2022 Fundación Española de Artroscopia. Published by Imaidea Interactiva in FONDOSCIENCE® (www.fondoscience.com). This is an Open Access article under license CC BY-NC-ND (www.creativecommons.org/licenses/by-nc-nd/4.0/).